

Effect of topical ethanolic extract of noni leaf on post-extraction wound by observation of wound diameter and osteoblast cells



CrossMark

Indah PR. Sabirin,^{1*} Ris Kristiana,² Erick Khristian,³ Mas KR. Kustiawan,⁴
Euis R. Yuslianti¹

Abstract

Objective: The aim of this study is to determine the effect of noni leaf ethanol extract gel on post extraction wound of rabbit teeth observed from wound diameter and osteoblasts cell count. Tooth extraction is one of the treatments performed in the oral region that cause wound. Application of substance or medicine might help accelerate and improve wound healing.

Material and Methods: Twenty-four rabbits divided into three groups: negative control, positive control with 10% povidone iodine, and treatment group with 10% ethanol extract gel of noni leaf. The tooth was extracted from the mandibular left incisor. The diameter of the wound area was examined on day 0, 3, 7, and 14 while the

osteoblasts cell count was obtained from rabbits' specimen in each group on 14th day. Measurement of wound diameter was done by using calipers, while the number of osteoblasts were calculated using toluidine blue histochemistry stain and light microscope with 400x magnification.

Results: The ratio of wound diameter were better in treatment group with significant difference ($p=0.048$) while osteoblasts cell count were not significantly different among all groups.

Conclusion: Topical application of noni leaf had an effect in decreasing mucosal wound diameter but there was not any evidence yet that it was increased osteoblast cells on socket wound healing process.

Keywords: Noni leaf, Osteoblasts, Post extraction, Wound diameter, Wound healing

DOI: [10.15562/jdmfs.v7i3.1410](https://doi.org/10.15562/jdmfs.v7i3.1410)

¹Department of Oral Biology, Faculty of Dentistry, Universitas Jenderal Achmad Yani, Cimahi, Indonesia

²Department of Pathology Anatomy, Faculty of Medicine, Universitas Jenderal Achmad Yani Cimahi, Indonesia

³Health Analyst Program, Institute of Health Science Jenderal Achmad Yani, Cimahi, Indonesia

⁴Faculty of Dentistry, Universitas Jenderal Achmad Yani Cimahi

Introduction

Tooth extraction is a dental treatment indicated for certain disorder of the tooth. Tooth extraction will cause a wound in the oral mucosa and periodontal. The same phase of wound healing - inflammatory phase, proliferative phase, and remodeling phase - will also happen on post extraction wound, as well as formation of new bone in the socket that involves bone formation cells such as osteoblasts. Unlike mucosal wound healing, tooth socket healing also involves macrophage and osteogenic cells from the bone marrow around the alveolar bone, besides epithelial cells from the mucosal surface.¹⁻³ Wound healing is a physiological process, but sometimes exogenous substance or medications are necessary to help accelerate wound healing and inhibit things that interfere ideal wound healing process. Bone formation during post extraction repair usually started at day 10 after extraction, and it requires cells such as osteoblasts.^{2,4} Noni (*morinda citrifolia*) is a plant by far found in any part of Indonesia which the leaf had been used empirically as medication for wound healing. There are a lot of active phytochemical constituents in noni leaf, and some of these ingredients that benefits in wound healing are alkaloids, saponin, flavonoids, and anthraquinon. Alkaloids can help wound improve wound healing

as antibacterial agent by inhibiting bacterial DNA synthesis and bacteria cell wall destruction. Beside its antibacterial property, flavonoid in noni leaf can increase fibroblast proliferation on proliferative phase. It can also inhibit TNF- α expression which mediate PMN cells migration, fibroblast apoptosis, and synthesize matrix metalloproteinase (MMP) from macrophage. Other property of flavonoid is to increase insulin-like growth factor 1 (IGF-1) expression that responsible on fibroblast proliferation and collagen synthesis. Scopoletin is beneficial for extending capillary vascularization to help inflammatory process, and ascorbic acid acts as antioxidant which can accumulate dalam sel darah putih to improve inflammatory process.⁵⁻⁸ Our previous study found out that 10% gel ethanol extract of noni leaf 10% can help acceleration of wound healing of palatal wound healing of Wistar rats examined clinically. Based on our other study, paste formulation of 10% noni leaf extract found to be improving oral mucosa wound healing, observed from fibroblast cell count 2016.^{9,10} Histochemistry stain is needed to facilitate identification of cells and tissue, and in this study toluidine blue stain is used to observe osteoblast cells formed during osteal wound healing, in which formation of bone started at 10th day after extraction.^{2,11}

*Correspondence to: Indah PR. Sabirin. Department of Oral Biology, Faculty of Dentistry, Universitas Jenderal Achmad Yani, Cimahi, Indonesia
indah.puti@lecture.unjani.ac.id

Received 31 January 2021

Revised 1 July 2021

Accepted 29 July 2021

Available online 1 December 2022

Table 1. Post extraction wound diameter

	Negative control	Positive control	Treatment	P
	Mean diameter (mm)			
Day 0	4	4	4	
Day 3	3.75	3.8	3.2	0.048*
Day 7	3.55	3.35	0.85	
Day 14	2.55	2.05	0	

* Anova test result $p < 0,05$ considered significant

Table 2. Osteoblast cell count on day 14

	Negative control	Positive control	Treatment	P
	Mean cell count on 10 field of vision			
	17.3	15.2	16.3	0.949

Anova test result




Figure 1. Socket specimen in 400x magnification, toluidine blue stain. From left to right: Negative control; Positive control; Treatment. Black arrow showed osteoblast cells.

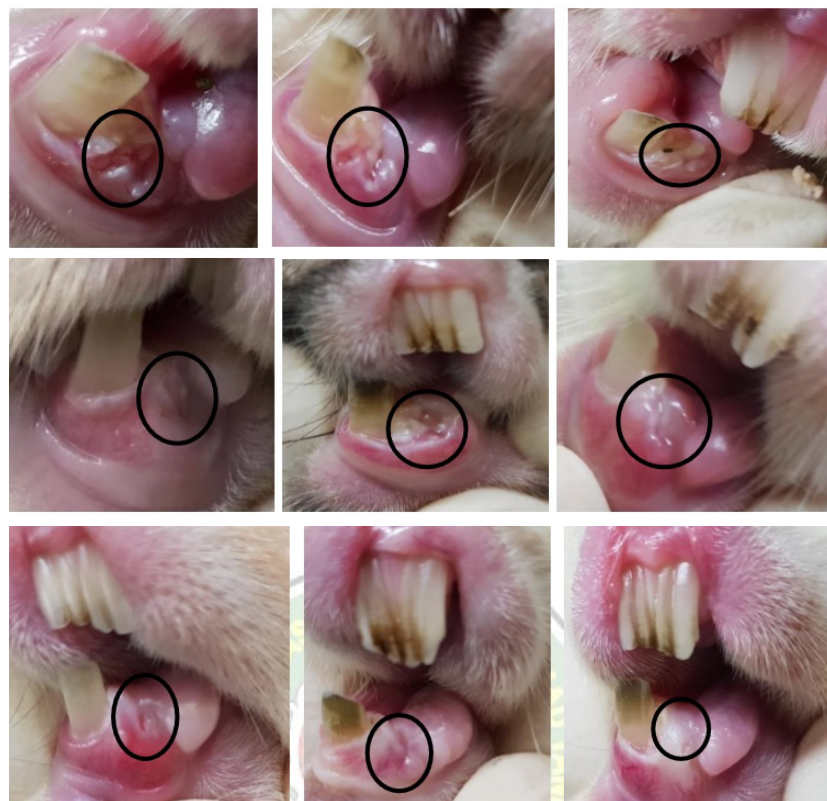


Figure 2. Clinical wound healing on day 3, 7, and 14. From left to right: negative control group, positive control group, treatment group.

Material and Methods

Materials used in this research is noni leaf which extracted with ethanol and prepared as 10% w/w concentration with using hydroxypropyl methylcellulose (HPMC) gel. Other materials used were 10% povidone iodine, ketamine for general anesthetic purpose, 70% alcohol, and physiologic saline solution. Surgical materials and hemostat for tooth extraction, instruments for leaf extraction, as well as instruments for bone decalcification and formulating histochemical specimen were also prepared. Twenty-four healthy rabbits (*Oryctolagus cuniculus*) utilized as post tooth-extraction wound healing model. This study had received ethical clearance from Research Ethical Committee of Universitas Padjadjaran Medical Faculty (no. 1428/UN6.KEP/EC/2018). The research including data analysis was carried on in Medical Faculty and Pharmacy Faculty of Universitas Jenderal Achmad Yani, Cimahi, West Java from January 2019 to November 2021.

Tooth extraction of left lower incisor was performed on all rabbits using hemostat clamp, following general anesthetic prepared with 20mg/kg dose of ketamine. 24 rabbits were divided into three groups, each group comprised of 8 rabbits; which were negative control with physiologic saline solution to cleanse the wound after extraction, positive control with 10% povidone iodine application and treatment group with 10% ethanol extract gel of noni leaf application. Treatment and positive control groups receive substance application every day and the wound examined on day 0, 3, 7, and 14 to represent inflammatory, proliferative, and remodeling phase. On day 14 two rabbits from each group were terminated to achieve histochemistry specimen of tooth socket. Clinical wound healing was done by measuring post extraction wound diameter, while microscopic examination was carried on by counting osteoblast cells on decalcified and toluidine-blue-stained specimen using 400x magnification in 10 fields of view [Figure 1](#).¹¹⁻¹⁴

Results

The measurement of tooth socket wound diameter on day 0, 3, 7, and 14 showed more distinctive wound diameter decrease in treatment group compared to negative control or positive control group. This difference could be seen clearly on day seven where wound diameter mean of treatment group had turned from 3.2mm into 0.85mm while on positive control and negative control subsequently was 3.55mm and 3.35mm each on

the seventh day [Figure 2](#). On the 14th day, wound condition in treatment group had closed completely, unlike the other groups where visible socket wound was still appeared. From Anova test result, it could be discovered that there was significant difference among the result of every group [Table 1](#).

However, in the observation of osteoblast cells around the socket on day 14 [Table 2](#), there were not any significant differences among every group's cell count. The most total mean count of osteoblasts cells was on negative control group, but the amount was not very numerous compared to treatment and positive control group. Presumably this thing happened because up to 14th day of observation, active ingredients of noni leaf were not absorbed deeper to recover bone healing, but only performed in improvement of mucosal wound repair.

Discussion

Wound can be defined as loss of tissue continuity, and this could be occurred from tooth extraction treatment. Wound caused by tooth extraction will encounter repair process in the mucosa as well as in the bone. One of the importance of medication during wound healing is to help accelerate wound healing process and avoid complications in the wound and as a result of it. Noni leaf is a part of noni plant that traditionally used to help improve wound healing. Some studies had demonstrated that noni leaf extract could help wound healing on the skin and oral mucosa. This was also showed on the result of this study from visual observation result of post-extraction wound diameter, where on day 7 and 14, treatment group with 10% ethanolic extract of noni leaf application wound was healed earlier compared to other groups.^{1,2,9,15}

Wound diameter decrease within treatment group might occurred because of active ingredients of noni leaves performed on wound healing process on all phases. Alkaloid, scopoletin, saponin, flavonoid, and anthraquinone functioned throughout inflammatory phase which happened just after the injury and hemostatic stage until third day. Flavonoid inhibited reactive oxygen species (ROS) release so that inflammatory response would occur more immediately. Anthraquinone and saponin acted as antibacterial agent which also prevent infection through this phase. On day 7, or during proliferative phase, angiogenesis, granulation tissue formation, early wound constriction, and early epithelization took placed. Next, started around 14th day, remodeling phase followed, where the wound closed superficially, collagen tissue below the epithelium matured,

and started to arrange in order. Noni leaf active composition especially flavonoids, worked in these two phases by inhibiting expression of TNF- α from the macrophage. These TNF- α inflammatory cytokines would mediate PMN migration, start fibroblast cells apoptosis, and synthesize MMP which might slow down wound healing process. Flavonoid as an antioxidant also help increase fibroblast proliferation and collagen synthesis in the lamina propria.^{5-8,16}

Osteoblasts are osteogenic cells which are important for alveolar bone regeneration. They are derived from mesenchymal cells, and located at the surface of the bone where bone formation occurs. Osteoblasts served in secretion of organic matrix of the bone and bone mineralization, as well as controlling regulation of osteoclasts during bone healing. During socket wound healing after tooth extraction, at first, blood clot would fill the socket and mucosal wound healing phases follows with the cell's origin from the bone around the socket, unlike mucosal wound healing.^{2,17} In this study, the number of osteoblasts cells were also counted to examine the effect of noni leaf active ingredients for post extraction bone healing. From the observation result, however, the amount of osteoblast cells on day 14 among every group were not significantly different. Since noni leaf has an active constituent that helped osteal tissue and cells formation - which are flavonoids such as quercetin, the effect might actually be different with the extract application.^{5,18} This result might be because of topical application of the extract only worked on the mucosal and connective tissue wound healing. Topical application of medicine is intended to give local effect to overcome signs and symptoms in the body. Topical formulation can work by giving protection to the tissue, influence metabolism process locally, and help eliminating microorganisms. Wound healing using topical medication depends on the type of preparation and absorption capacity of the medicine.^{14,19,20} Previous studies results showed that noni leaf extract comprised of active component that could help improve and increase wound healing.^{9,10} In this study, however, absorption effect of active constituents to the bones didn't seem to occur although mucosa wound were already improved within the treatment group compared to control. This most likely suggested as the active constituent effects were only functioned superficially and might have not absorbed fully until 14th day of observation since bone healing started on 10th day.²

Conclusion

This study showed that 10% topical ethanolic extract

gel of noni leaf could help improve and accelerate post-extraction mucosal wound closure in 14 days. On the other hand, the evidence of its benefit on bone healing indicated by osteoblast cell amount had not been found out. These results showed that further research with longer observation time or different formulation was necessary to demonstrate that the active ingredients of noni leaf can promote tissue repair.

Acknowledgment

The authors would like to thank the research institution and community service of Universitas Jenderal Achmad Yani for the funding support, also to Prof Afifah B Sutjiatmo and Dr. Fikri Alatas of Pharmacy Faculty in Universitas Jenderal Achmad Yani, for their assistance in formulating ethanolic extract gel of noni leaf.

Conflict of interest

The authors report no conflict of interest.

References

- Andersson L, Kahnberg KE, Pogrel MA. Essentials of oral and maxillofacial surgery. Philadelphia: Wiley Blackwell; 2014. p. 63-66
- Srinivas B, Das P, Rana MM, et al. Wound healing, and bone regeneration in post extraction sockets with and without platelet-rich fibrin. *Ann Maxillofac Surg* 2018;8: 28-34.
- Gomes PS, Daugela P, Poskevicius L, et al. Molecular and cellular aspects of socket healing in the absence and presence of graft materials and autologous platelet concentrates: A focused review. *J Oral Maxillofac Res* 2019;10: e2.
- Politis C, Schoenaers J, Jacobs R, et al. Wound healing problems in the mouth. *Front Physiol* 2016;7: 507.
- Ali M, Singh P, Singh L, et al. Phytochemical constituents, and pharmacological activities: profile of morinda citrifolia. *W Jour Pharm Res* 2020;29: 421-433.
- Nayak BS, Sandiford S, Maxwell A. Evaluation of the wound-healing activity of ethanolic extract of Morinda citrifolia L. Leaf. *eCAM* 2007;6: 351-356.
- Kumar KT, Panda DS, Nanda UN, et al. Evaluation of antibacterial, antifungal, and anthelmintic activity of morinda citrifolia L. (Noni). *Int J Pharm Tech Res* 2010;2: 1030-1032.
- Kakad SL, Pise SS, Dhembare AJ. Evaluation of phytochemical, antibacterial, antifungal activities of leaf extracts of morinda citrifolia (Linn) S. L. *Der Pharmac Sinica* 2015;6: 9-12.
- Yuslianti ER, Sabirin, IPR, Sutjiatmo AB. Effectiveness of noni (morinda citrifolia L.) leaves extract gel as standardized traditional medicine to accelerate oral mucosa wound healing on wistar rats. *Res J Med Plant* 2014;8: 156-166.
- Sabirin IPR, Yuslianti ER. Beneficence of ethanolic extract paste of noni (morinda citrifolia L.) leaves on oral mucosa wound healing by examination of fibroblast cells. *J Dent Ind* 2016;23: 59-63.
- Wang C, Wang X, Xu X, et al. Bone microstructure and regional distribution of osteoblast and osteoclast activity in the osteonecrotic femoral head. *PLoS One*. 2014;9: e96361.
- Vlaminck L, Verhaert L, Steenhaut M, et al. Tooth extraction techniques in horses, pet animals and man. *Vl Dierg Tijds* 2007;76: 249-261.
- Tanaka T. Calcium dynamics in the healing of tooth extraction sockets in mice evaluated using ⁴⁵Ca-autoradiography and Electron Probe Micro Analysis. *Nippon Kokoka Gakkai Zasshi* 2006;55: 23-33.
- Pereira RF, Bartolo PJ. Traditional therapies for skin wound healing. *Adv Wound Care* 2016;5: 208-229.
- Cho H, Lynham AJ, Hsu E. Postoperative interventions to reduce inflammatory complications after third molar surgery: review of the current evidence. *Aus Dent A*. 2017;62: 412-419.
- Assi RA, Darwis Y, Abdulbaqi IM, et al. Morinda citrifolia (Noni): A comprehensive review on its industrial uses, pharmacological activities, and clinical trials. *Arab Jour Chem* 2017;10: 691-707.
- Gonzalez ACO, Costa TF, Andrade ZA, et al. Wound healing - A literature review. *An Bras Dermatol* 2016;91: 614-620.
- Wong SK, Chin KY, Ima-Nirwana S. Quercetin as an agent for protecting the bone: a review of the current evidence. *Int J Mol Sci* 2020;21: 6448.
- Hung C, Lin Y, Zhang L, et al. Topical delivery of silymarin constituents via the skin route. *APS* 2010;31: 118-126.
- Patil PB, Datir SK, Saudagar RB. A Review on topical gels as drug delivery system. *JDDT*. 2019;9: 989-994.



This work is licensed under a Creative Commons Attribution